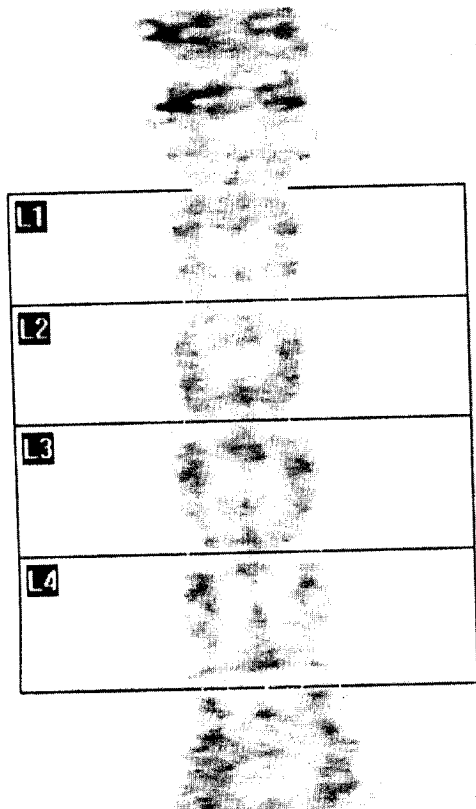


Name: CHYUMAKOVA, I K  
 Patient ID: CIK-AMB  
 DOB: 08 February 1961

Sex: Female  
 Ethnicity: White

Height:  
 Weight:  
 Age: 51

Referring Physician:



k = 1.149, d0 = 41.9  
 116 x 126

**Scan Information:**

Scan Type: f Lumbar Spine  
 Analysis: 11 January 2013 12:04 Version 12.6:3  
 Lumbar Spine

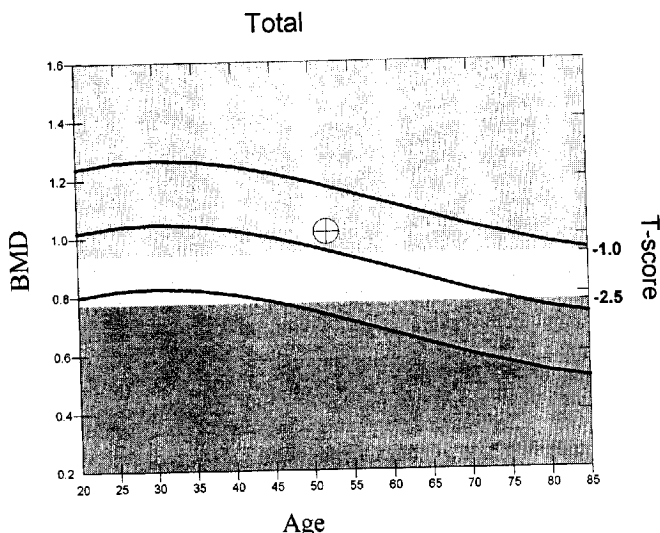
Operator:  
 Model: Discovery A (S/N 82263)  
 Comment:

**DXA Results Summary:**

Region	Area (cm <sup>2</sup> )	BMC (g)	BMD (g/cm <sup>2</sup> )	T-score	Z-score
L1	10.03	8.91	0.889	-0.3	0.4
L2	11.21	11.65	1.040	0.1	0.9
L3	12.72	13.56	1.066	-0.2	0.7
L4	14.11	14.75	1.045	-0.6	0.3
<b>Total</b>	<b>48.06</b>	<b>48.87</b>	<b>1.017</b>	<b>-0.3</b>	<b>0.6</b>

Total BMD CV 1.0%, ACF = 1.044, BCF = 1.009, TH = 8.257

WHO Classification: Normal  
 Fracture Risk: Not Increased



Fracture Risk  
 Not Increased Increased High  
 T-score vs. White Female; Z-score vs. White Female. Source:Hologic

**Physician's Comment:**

*β максимум эгд  
 нзбонорума (L1-L4)  
 мтк в норме  
 T = -0,3*

**HOLOGI**

*M. OI. 137.*